

**PATIENT**

Daisy Fanelli

**SPECIES**

Canine

**BREED**

Chihuahua Mix

**SEX**

Female Spayed

**AGE**

9 years

**WEIGHT**

19.8lbs

**INTERPRETED BY**

Maggie Machen Lamy,  
DVM, DACVIM  
(Cardiology)

**IMAGING PERFORMED BY**

Dana Alterman,  
RDCS, LVT

**HOSPITAL NAME**

Eubank Animal Clinic

**REFERRING VET**

Dr. Warrick

**INVOICE**

31755

**DATE**

7/10/23

**PRESENTING CLINICAL SIGNS**

History: Presented to ER for recent exercise intolerance, dry cough and 1-2-day progressive increase in breathing effort with tachypnea. Hospitalized for 12 hours on O2 and started meds.  
-Current medications: Pimobendan 0.25mg/kg PO BID + Lasix 1.4 mg/kg PO BID.

**ELECTROCARDIOGRAPHIC FINDINGS**

A six lead ECG is available at 25mm/s; 10mm/mV. The average heart rate is 190bpm (range 150-214bpm). The rhythm is sinus in origin, with a p for every QRS complex and vice versa. The P wave morphology is positive with a normal dimension. Normal PR. The QRS morphology is positive with normal dimension. MEA is normal. A single APC is noted. No VPCs, pauses or other dysrhythmias observed.

ECG diagnosis: Normal sinus rhythm. Periods of sinus tachycardia. Single isolated APC.

**ECHOCARDIOGRAM FINDINGS**

2D, m-mode, color flow and doppler imaging is available. The mitral valve is diffusely thickened with prolapse into the left atrial lumen. There is severe eccentric mitral regurgitation present. There is severe left atrial enlargement. There is mild left ventricular dilation. Left ventricular systolic function is hyperdynamic. There is normal systolic flow velocity across the aortic valve. The aortic valve appears trileaflet with normal mobility. The main pulmonary artery is prominent. The pulmonic valve is normal in appearance. Mild right heart enlargement (subjective). Mild thickening of the tricuspid valve with mild tricuspid regurgitation. TR velocity is normal. No obvious pulmonary hypertension. No pericardial/pleural effusion seen. Hyperechoic lesion associated with the heart base; 2.3cm x 1.9cm. No impingement on great vessels or cardiac chambers is noted.

**CARDIAC CHART**

CANINE CARDIAC PARAMETERS	MR VMAX (m/s)	TR VMAX (m/s)	LA/AO (Boon method)	LA/AO (Heart Base; Swe)	FS (%)	EF (%)	EPSS (cm)
NORMAL PARAMETER	4.5-5.5	<2.7	1.3	<1.6	28-40	40-100	<0.6
PATIENT	NM	2.7	NM	2.2	63	92	NM
CANINE CARDIAC PARAMETERS	HR (BPM)	AV VMAX (m/s)	PV MAX (m/s)	BODY WEIGHT (kg)	LA 2D short axis Base view (cm)	LVIDd Avg; 2D and m-mode short axis (cm)	LVIDs Avg; 2D and m-mode short axis (cm)
NORMAL PARAMETER	50-100	0.7-1.7	0.7-1.6	BELOW	BELOW	BELOW	BELOW
PATIENT	NM	1.3	0.8	9.0	2.9	2.7	1.0
*Normal chamber parameters expressed as a mean value (SD)				3	1.27 (5.3)	2.46 (2.46)	1.36 (5.5)
<b>BODY WEIGHT DEPENDENT PARAMETERS</b>				5	1.40 (4.5)	2.74 (5.2)	1.60 (4.7)
<i>*Note: All measurements based upon multi-modal images and methods. An average value is reported.</i>				10	1.50 (3.8)	3.27 (3.5)	2.06 (3.1)
				15	1.83 (2.0)	3.71 (2.4)	2.43 (2.1)
				20	2.02 (1.9)	4.14 (2.2)	2.80 (2.0)
				25	2.18 (2.4)	4.48 (2.9)	3.10 (2.5)
				30	2.33 (3.3)	4.83 (3.9)	3.39 (3.4)
				35	2.48 (4.3)	5.17 (5.0)	3.69 (4.5)
				40	2.62 (5.2)	5.48 (6.1)	3.96 (5.4)
				50	2.88 (7.1)	6.07 (8.3)	4.46 (7.4)

Adapted from June Boon, Veterinary Echocardiography, 1998  
Rishniw M and Hollis NE, J Vet Intern Med 2000; 14:429-435  
Hansson et al, Vet Rad and Ultrasound 2002  
Bonagura et al. Echocardiography: principles of interpretation, Vet Clin North Am 15:1177, 1995



**PATIENT**

Daisy Fanelli

**SPECIES**

Canine

**BREED**

Chihuahua Mix

**SEX**

Female Spayed

**AGE**

9 years

**WEIGHT**

19.8lbs

**INTERPRETED BY**

Maggie Machen Lamy,  
DVM, DACVIM  
(Cardiology)

**IMAGING PERFORMED BY**

Dana Alterman,  
RDCS, LVT

**HOSPITAL NAME**

Eubank Animal Clinic

**REFERRING VET**

Dr. Warrick

**INVOICE**

31755

**DATE**

7/10/23

**INTERPRETATION OF THE FINDINGS & FURTHER RECOMMENDATIONS**

Chronic degenerative valve disease causing severe mitral and mild tricuspid regurgitation. Severe LA dilation is noted, which supports the recent diagnosis of CHF. A cardiac tumor which appears to be associated with the aortic root is also identified. The most likely tumor type given this location and breed is a chemodectoma, however other differentials cannot be ruled out (ectopic parathyroid, hemangiosarcoma, etc.). The ECG is unremarkable with normal sinus tachycardia. Rare APCs are not surprising in a patient with severe structural disease in crisis. No treatment is warranted.

Chemodectomas are often incidental findings, only causing clinical signs if blood flow is obstructed, pericardial effusion occurs, or a metastatic lesion causing systemic issues. The prognosis with cardiac chemodectomas is fair, with an MST of 1-2 years; however, outcome in this case is likely limited by CVD/CHF with a more guarded prognosis of <1year. The limiting factor is with cardiac neoplasia is often hemorrhage into the pericardium. Other sequelae include impingement of cardiac blood flow secondary to tumor growth, or metastasis to the thorax or abdomen. At this time this is considered an incidental finding (although it may be contributing to a clinical cough), and is unlikely to be causing clinical issues. Compression of the MPA and branches is not overtly seen; however, peripheral impingement is possible. Consider systemic screening for evidence of metastasis (AUS, etc.) in addition to referral for advanced imaging such as thoracic CT scan to further investigate the lesion. It is important to note that the tumor is INDEPENDENT of left heart disease; rather, this would lead to right-sided cardiomegaly and development of effusions (as compared to recent pulmonary edema).

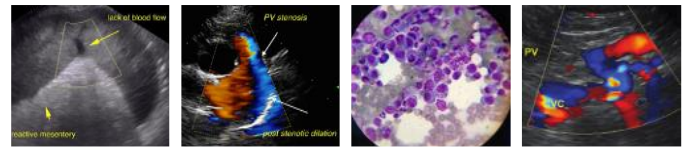
Given the severity of left-heart disease, the diagnosis of CHF is supported and continued cardiac support is recommended as below including diuretic therapy. Hydrocodone may also be beneficial in the event a mechanical cough persists due to cardiomegaly/mechanical obstruction. Should effusions develop in the future, reassessment is advised as further tumor growth/impingement/infiltration is certainly possible going forward.

Omega fatty acid supplementation and mild salt restriction may also be of some long-term benefit. Monitor for development of a cough, labored breathing, exercise intolerance or collapse episodes. Serial monitoring of SRRs is recommended as the best way to screen for progression towards CHF at home.

**PLAN**

Screening BP recommended. Consider CT/AUS/systemic screening. Continue Furosemide 1-2mg/kg PO q12h. Continue Pimobendan 0.25-0.3mg/kg PO q12h. Pending BP >130mmHg, institute ACEI 0.5mg/kg PO q12h. Institute Spironolactone 1-2mg/kg PO q12h. Consider hydrocodone if needed.

A recheck echocardiogram is recommended in 4-6 months to screen for progression, sooner if clinical signs arise.



**PATIENT**

Daisy Fanelli

**SPECIES**

Canine

**BREED**

Chihuahua Mix

**SEX**

Female Spayed

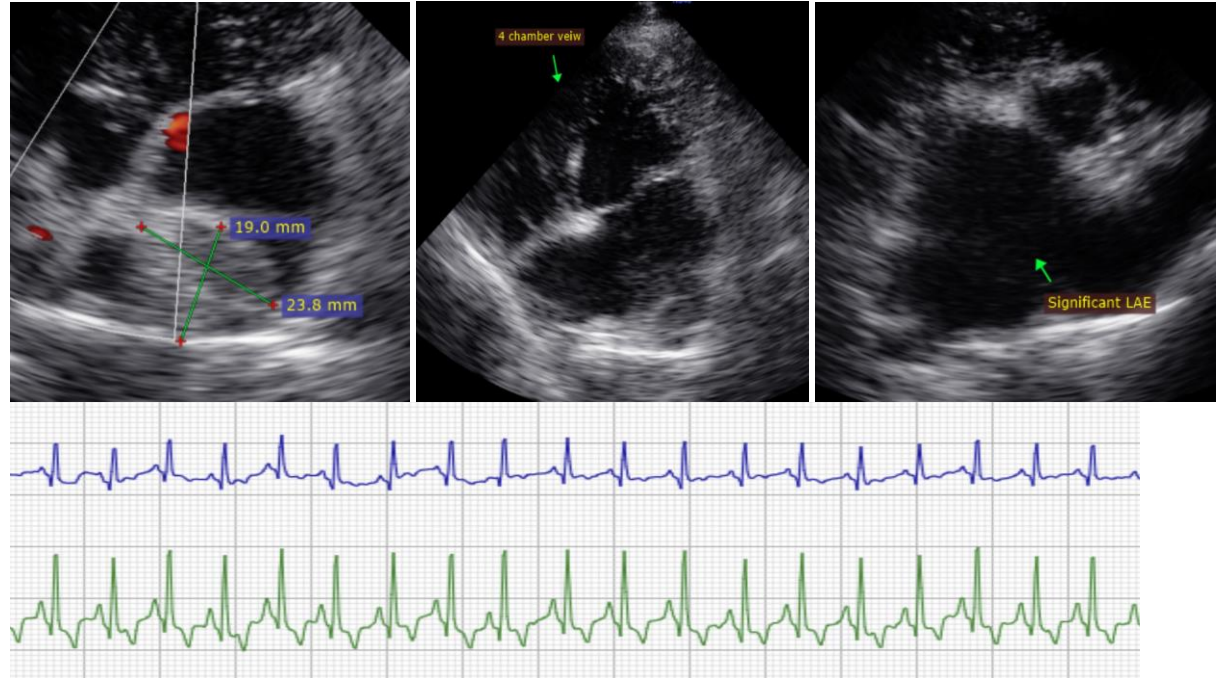
**AGE**

9 years

**WEIGHT**

19.8lbs

**IMAGES**



**INTERPRETED BY**

Maggie Machen Lamy,  
DVM, DACVIM  
(Cardiology)

**IMAGING PERFORMED BY**

Dana Alterman,  
RDCS, LVT

**HOSPITAL NAME**

Eubank Animal Clinic

**REFERRING VET**

Dr. Warrick

**INVOICE**

31755

**DATE**

7/10/23

The information and recommendations provided are based on the images presented by the referring veterinarian. No evaluation can be communicated regarding pathology that was not visible in the image/video clips provided.

Thank you for this referral. This report was generated using transcription software, and minor dictation errors may be present. If the clinical or image interpretation does not parallel your findings or if I can be of any further assistance, please contact me.

**Maggie Machen Lamy, DVM**  
Diplomate of the American College of Veterinary Internal Medicine (Cardiology)  
info@sonopath.com